



# Improving Vascular Access Outcomes

## FEMORAL ACCESS CONSIDERATIONS

---

### INTRODUCTION

Vascular access for percutaneous coronary and peripheral vascular catheterizations is an important but perhaps undervalued part of the percutaneous procedure. Vascular complications range from minor to major and have the potential to extend the patient's length of hospitalization and increase the associated procedural costs. Vascular access complications include hematoma, pseudoaneurysm, arteriovenous (AV) fistula, vessel laceration, intimal dissection, acute vessel closure (thrombosis of small artery lumen), retroperitoneal hemorrhage, thickening of the perivascular tissues, neural damage, infection, venous thrombosis, and pericatheter clot.

The most common access site for percutaneous coronary and peripheral vascular catheterizations is the common femoral artery and vein. One of the ways to prevent femoral access complications is by paying particular attention to specific patient and access site selection.

### LITERATURE REVIEW

The American College of Cardiology – National Cardiovascular Data Registry (ACC-NCDR) study data was recently reported in the *Journal of Invasive Cardiology*. This registry data included a 166,680-patient sample and assessed the relative risk of serious complications following the use of hemostasis devices as compared with manual compression. The relative rates of these complications by gender was also assessed, including bleeding, occlusion, loss of distal pulse, dissection, pseudoaneurysm,

AV fistula, and associated death. The ACC-NCDR reported an overall serious adverse event rate related to vascular access of 1.56%.<sup>1</sup>

Cox et al. reported the rate of vascular complications in the *American Journal of Cardiology* in a retrospective review of 5,234 cardiac catheterizations and coronary interventions over a 19-month period. The authors discovered that the rate of complication was highest in extremely thin and morbidly obese patients and lowest in mildly obese patients. Cox reported an overall complication rate of 4.8%.

Patients with both radial and femoral access sites were studied, and complications included transfusion, surgical repair, retroperitoneal bleed, large hematoma, pseudoaneurysm, and AV fistula.<sup>2</sup>

Two publications examine the relationship between arteriotomy site and the risk for Retroperitoneal Hematoma (RPH). The first study, published in *JACC* (2005), retrospectively reviewed 3,508 PCI patients at Stanford University to determine the risk factors for RPH. Twenty-six patients (0.74%) were found to have experienced retroperitoneal hematoma over the four-year review period. Examination of the RPH patient records revealed three factors to be predictive for RPH: gender (female), Body Surface Area (BSA) < 1.73m<sup>2</sup>, and high femoral puncture. Other factors studied which were not predictive included heparin use, IIB IIIA use, sheath size, and use of closure device.<sup>3</sup>

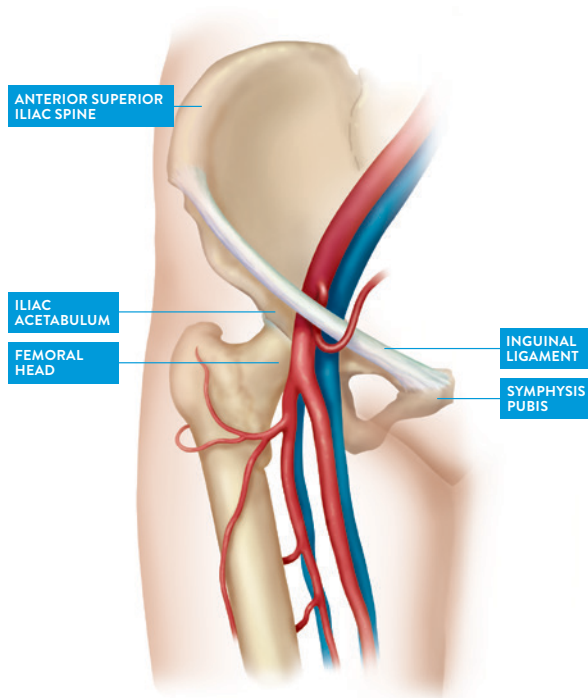
**Information contained herein for DISTRIBUTION globally.**

# Improving Vascular Access Outcomes

The second study was an abstract presented at TCT (2004) and published in the *American Journal of Cardiology*. This study examined the relationship between femoral arteriotomy location and risk of femoral access site complications after diagnostic and interventional cardiac catheterization procedures. A prospective group of 33 patients with femoral access site complications were subgrouped based on arteriotomy site. The study concluded that patients with arteriotomy location above the most inferior border of the inferior epigastric artery (IEA) are at an increased risk for retroperitoneal hematoma.<sup>4</sup>

## LANDMARKS USED FOR FEMORAL PUNCTURE

The inguinal ligament, extending from the anterior superior iliac spine to the pubic tubercle and running through the gap between the femoral head and the iliac acetabulum is the anatomic landmark that separates the external iliac artery from the common femoral artery.



The common femoral artery ends distally at the bifurcation into the superficial femoral artery and the profunda femoralis artery. The common femoral vein is a continuation of the popliteal vein and becomes the external iliac vein at the inguinal ligament. The femoral head is considered to be the optimal landmark for femoral puncture, with the middle 1/3 of the femoral head considered the “ideal” puncture site when using fluoroscopy.<sup>5</sup>

If manual compression becomes necessary, puncture above the inguinal ligament into the external iliac artery (EIA) and below the level of the bifurcation may predispose the patient to increased risk for bleeding complications because compression is against soft tissue rather than bone. Other complications associated with low puncture include AV fistula, thrombosis/embolism, and vessel occlusion with large sheaths.

Fluoroscopy of the femoral head is traditionally used rather than visualization of the inguinal skin crease during arterial or venous puncture. The inguinal crease may be unreliable, especially in obese patients where the panniculus may inferiorly displace the inguinal crease.<sup>5</sup> After the puncture has been made and the sheath inserted, other landmarks can be assessed by fluoroscopy to stratify the patient’s bleeding risk. Those landmarks are the inferior border of the inferior epigastric artery and the upper third of the femoral head.<sup>3,4</sup>

## DIAMETER SIZE OF FEMORAL VESSEL

The Instructions for Use (IFUs) of vascular closure devices recommend a common femoral artery and femoral vein diameter size of 5 mm or greater for use with these devices.<sup>6</sup> Schnyder et al. described in their 200-patient group a mean femoral artery diameter of 6.9 mm ± 1.4 mm. A statistically significant difference in diameter (smaller) of the common femoral artery was found in women, diabetics, and in patients with low body surface area (BSA). Additionally, the common femoral artery was found to be longer in tall patients.<sup>5</sup>

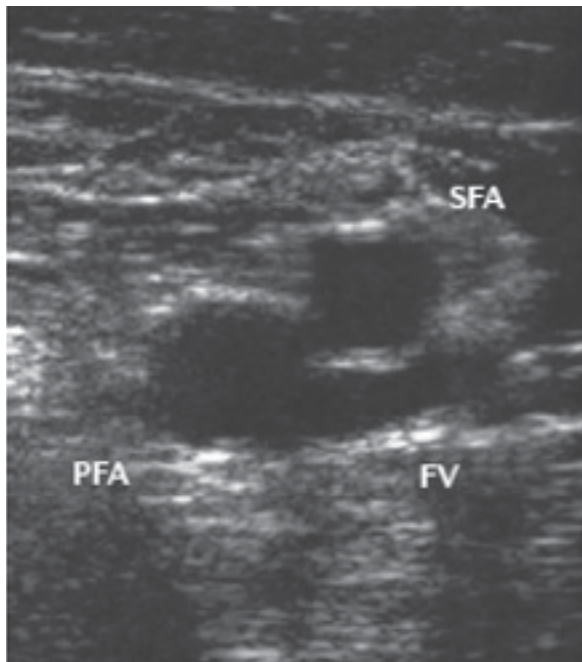
**Information contained herein for DISTRIBUTION globally.**

# Improving Vascular Access Outcomes

## ULTRASOUND GUIDED ACCESS

Ultrasound-guided access helps to identify the location of the CFA, CFV, femoral artery bifurcation, and inguinal ligament before the puncture. An analysis of the Femoral Arterial Access With Ultrasound Trial (FAUST) found that if using only fluoroscopic guidance to puncture the middle 1/3 of the femoral head, there would be a 95% chance of being above the CFA bifurcation and a 64% chance of being below the inferior border of the inferior epigastric artery. To improve accuracy, especially in high-risk procedures involving large-bore sheaths or anticoagulation, ultrasound guidance is recommended.<sup>7</sup>

The 1,004-patient FAUST study improved first-pass success rate, reduced number of attempts, reduced risk of venipuncture, and reduced median time to access in comparison to fluoroscopic guidance. Thus, ultrasound guidance reduced the incidence of any vascular complications by 59%. Ultrasound was also shown to be superior to fluoroscopy in the 31% of patients with high CFA bifurcation.<sup>8</sup>

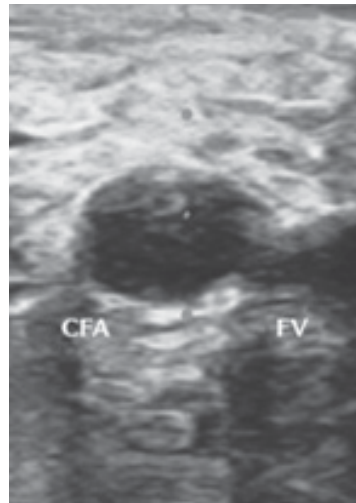


Source: Rao SV. *Nature Reviews Cardiology* 2013.

## ULTRASOUND GUIDANCE FOR ATHEROSCLEROSIS

Many patients undergoing percutaneous procedures are predisposed to atherosclerosis. An intravascular foreign body may be undesirable in these patients. It is also possible for needles to deflect off of plaque, and dilatation balloons may snag on plaque material, creating the risk of intra-arterial injection. Another bad sequelae may be embolization of plaque material into the artery or dissection of soft plaque material.

Ultrasound is particularly useful in visualizing calcification, which cannot be easily identified with fluoroscopy. In this way, puncture of diseased areas or the sidewall can be avoided. This reduces the risk of access site complication, especially when closure devices are being used.<sup>9</sup>



Source: Rao SV. *Nature Reviews Cardiology* 2013.

## CONSIDERATIONS

- Visualization with ultrasound of the femoral head, CFA bifurcation, and inguinal ligament prior to puncture.
- Visualization with ultrasound for calcification, especially when a closure device is being used.
- Puncture at the middle 1/3 of the femoral head when using only fluoroscopy.

**Information contained herein for DISTRIBUTION globally.**

©2024 Abbott. All rights reserved. MAT-2110990 v2.0

The information provided is not intended for medical diagnosis or treatment or as a substitute for professional medical advice. Consult with a physician or qualified healthcare provider for appropriate medical advices.

## References:

1. Tavis DR, Gallauresi BA, Rich SE et al. Risk of local adverse events following cardiac catheterization by hemostasis device use and gender. *The Journal of Invasive Cardiology* (2005) 16: 459-464.
2. Cox N, Resnic FS, Popma JJ, Simon DI, Eisenhauer AC, Rogers C. Comparison of the risk of vascular complications associated with femoral and radial access coronary catheterization procedures in obese vs. nonobese patients. *American Journal of Cardiology* (2004); 94: 1174-1177.
3. Farouque, HMO, Tremmel, JA, Shabari, FRS, Aggarwal, M, Fearon, WF, Ng, MKC, Rezaee M, Yeung AC. Risk factors for the development of retroperitoneal hematoma after percutaneous coronary intervention in the era of Glycoprotein IIB/IIIA Inhibitors and vascular closure devices. *Journal of the American College of Cardiology* 2005; 45: 363-368.
4. Sherev DA, Shaw RE, Brent BN. Angiographic predictors of life threatening femoral access site complications, Oral Abstracts, TCT 2004, *American Journal of Cardiology*, 2004; 94 (Suppl 6A): 125E.
5. Schnyder G, Sawhney N, Whisenant, B et al. Common femoral artery anatomy is influenced by demographics and comorbidity: implications for cardiac and peripheral invasive studies. *Cathet Cardiovascular Interventions* 2001; 53: 289-295.
6. Abbott Vascular 6F Suture-Mediated Closure System and Terumo Vascular Closure Device Instructions for Use.
7. Seto, Arnold H., et al. "Defining the common femoral artery: insights from the femoral arterial access with ultrasound trial." *Catheterization and Cardiovascular Interventions* 89.7 (2017): 1185-1192.
8. Seto, Arnold H., et al. "Real-time ultrasound guidance facilitates femoral arterial access and reduces vascular complications: FAUST (Femoral Arterial Access With Ultrasound Trial)." *JACC: Cardiovascular Interventions* 3.7 (2010): 751-758.
9. Seto, A. H., and M. S. Abu-Fadel. "Ultrasound-guided arterial access is the way to go." *Card Interv Today* (2012): 58-62.

Illustrations are artist's representations only and should not be considered as engineering drawings or photographs.  
Photo on file at Abbott.

**Information contained herein for DISTRIBUTION globally.**

### Abbott

3200 Lakeside Dr., Santa Clara, CA 95054 USA, Tel: 1.800.227.9902

[www.cardiovascular.abbott](http://www.cardiovascular.abbott)

©2024 Abbott. All rights reserved. MAT-2110990 v2.0

