

# Guidelines for Identifying Externalized Conductors on Radiographic Images

*These guidelines for determining the presence of externalized conductors were used by independent physician adjudicators in the Riata<sup>®</sup> Lead Evaluation Study and can aid in the radiographic assessment of patients with Riata<sup>®</sup> and Riata<sup>®</sup> ST leads*



ST. JUDE MEDICAL<sup>™</sup>

MORE CONTROL. LESS RISK.


# Examples of Intact Riata<sup>®</sup> Lead Bodies




ST. JUDE MEDICAL<sup>™</sup>

MORE CONTROL. LESS RISK.

# Riata Lead Body Cross-Section



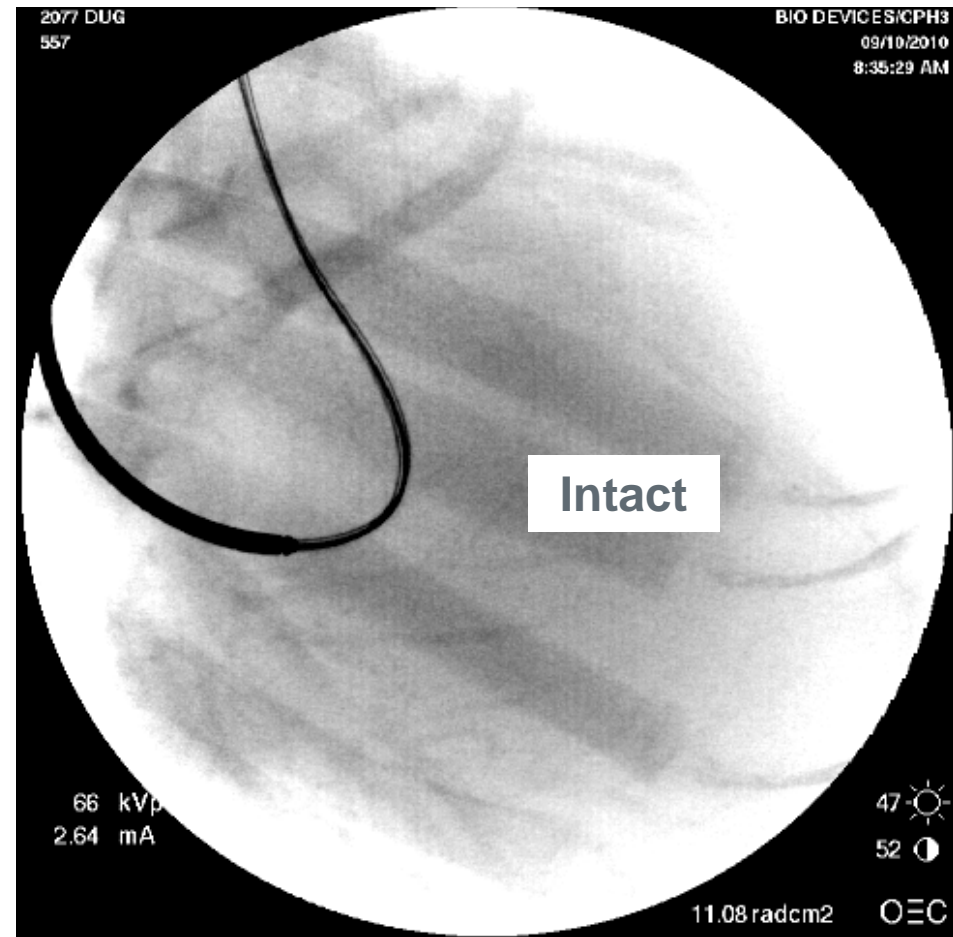
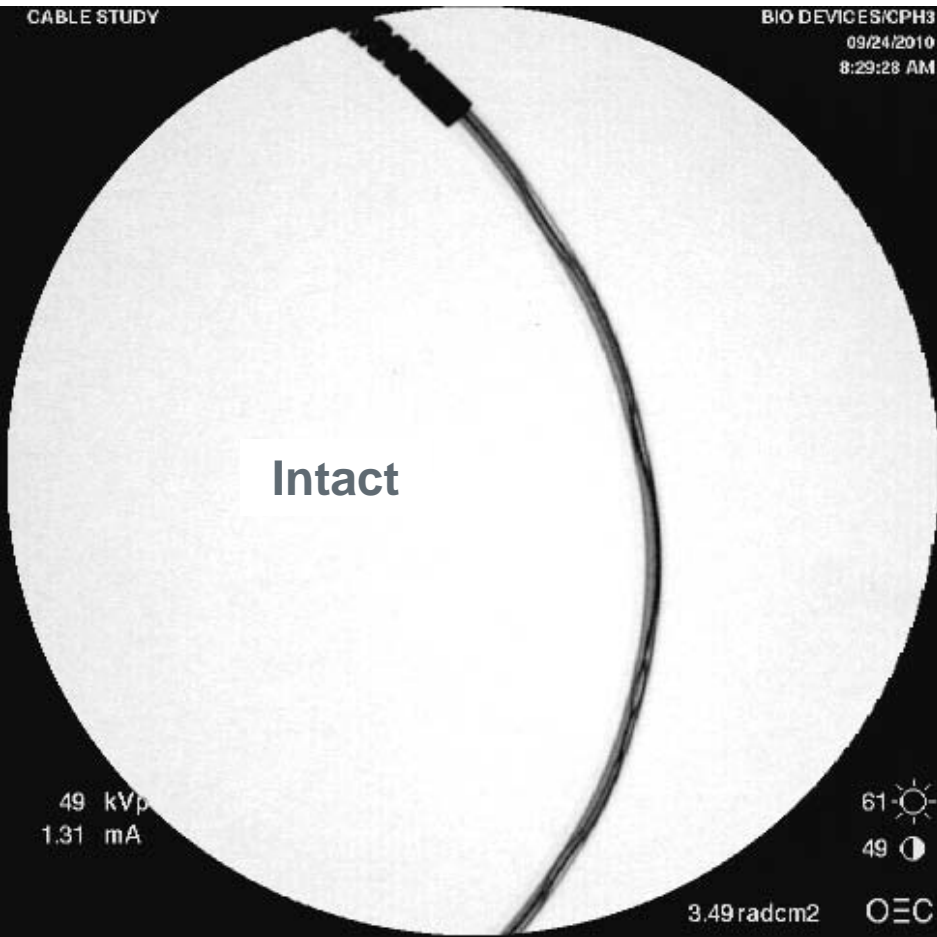
**Riata 8F/Riata ST**  
(except for 1582/72)



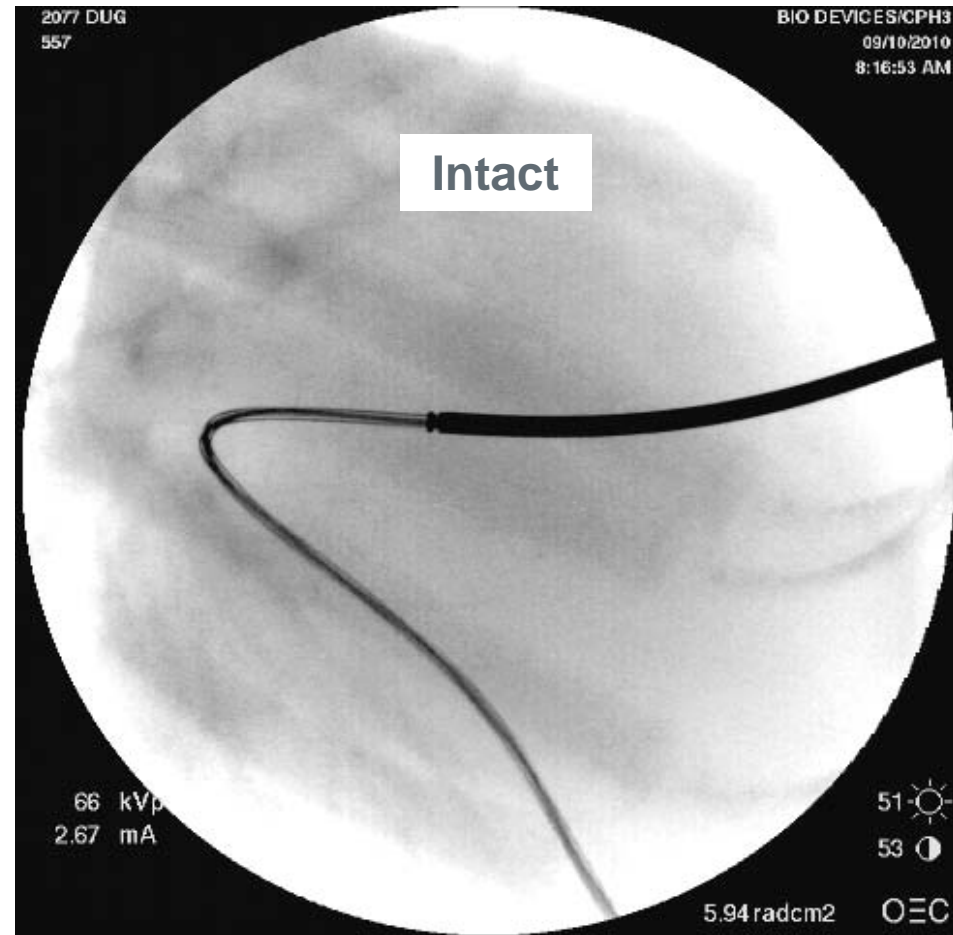
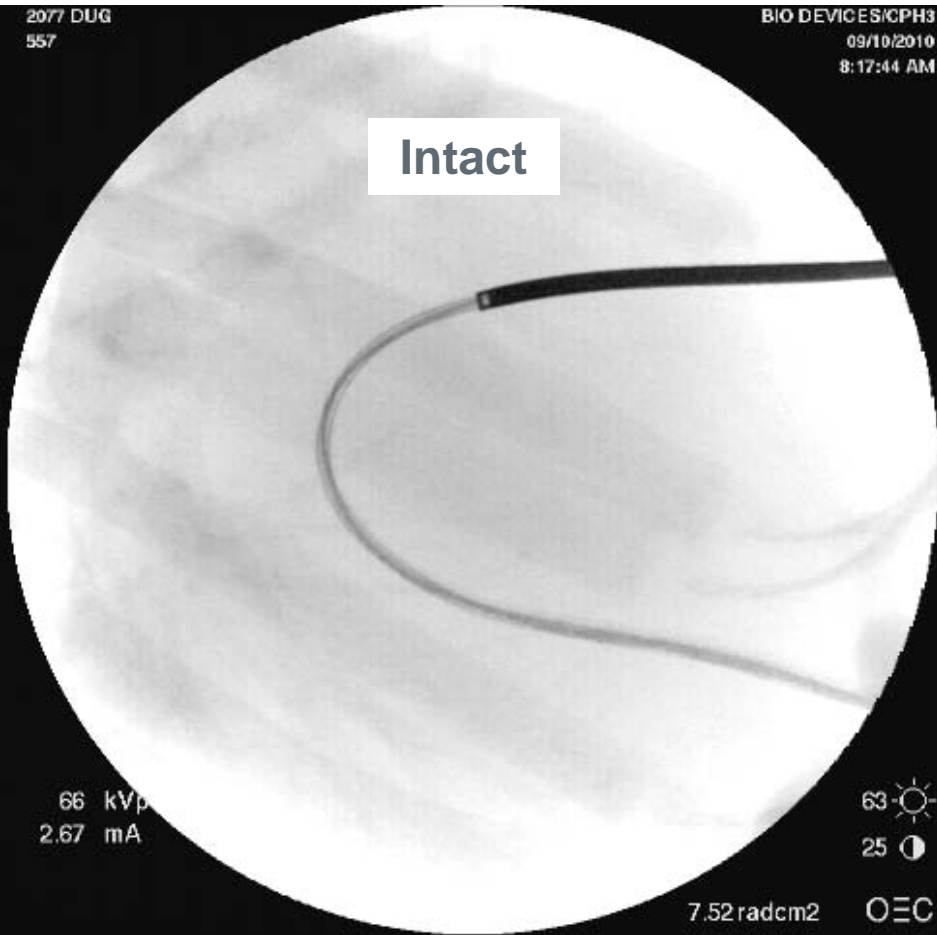**Riata 1582/72**

The opposing cable lumens combined with the greatest separation between cables and the centerline make the cables appear distinct in fluoro images

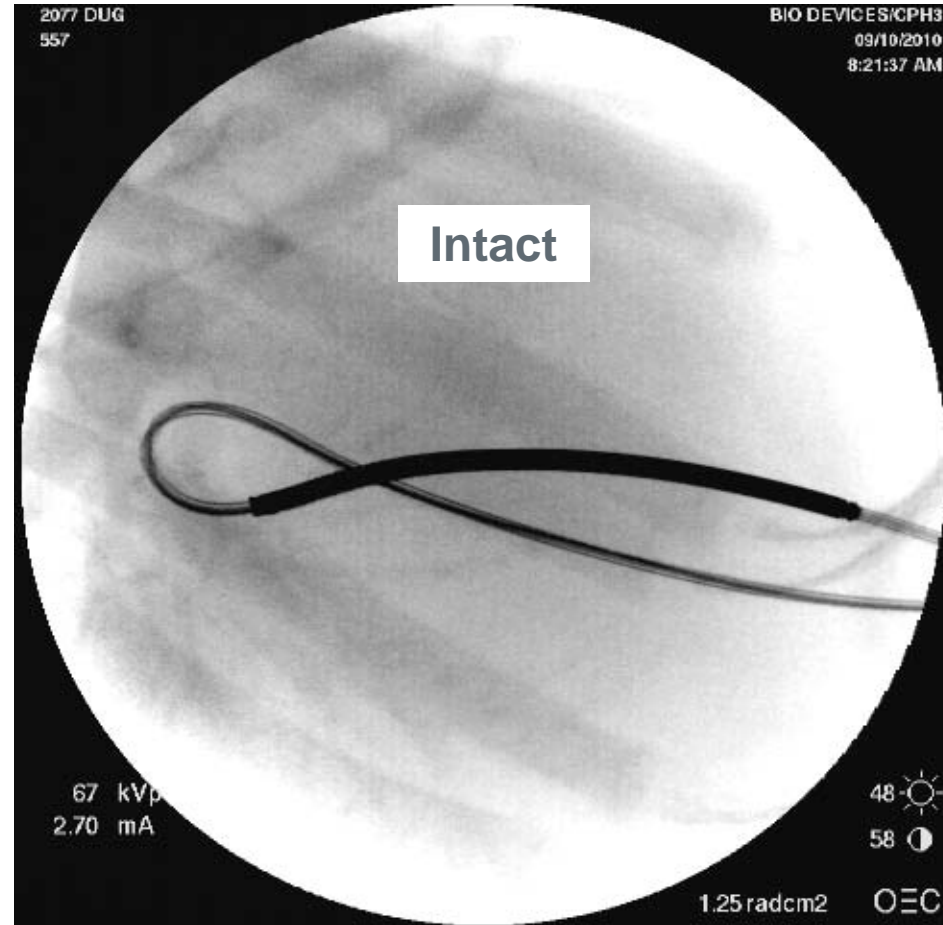
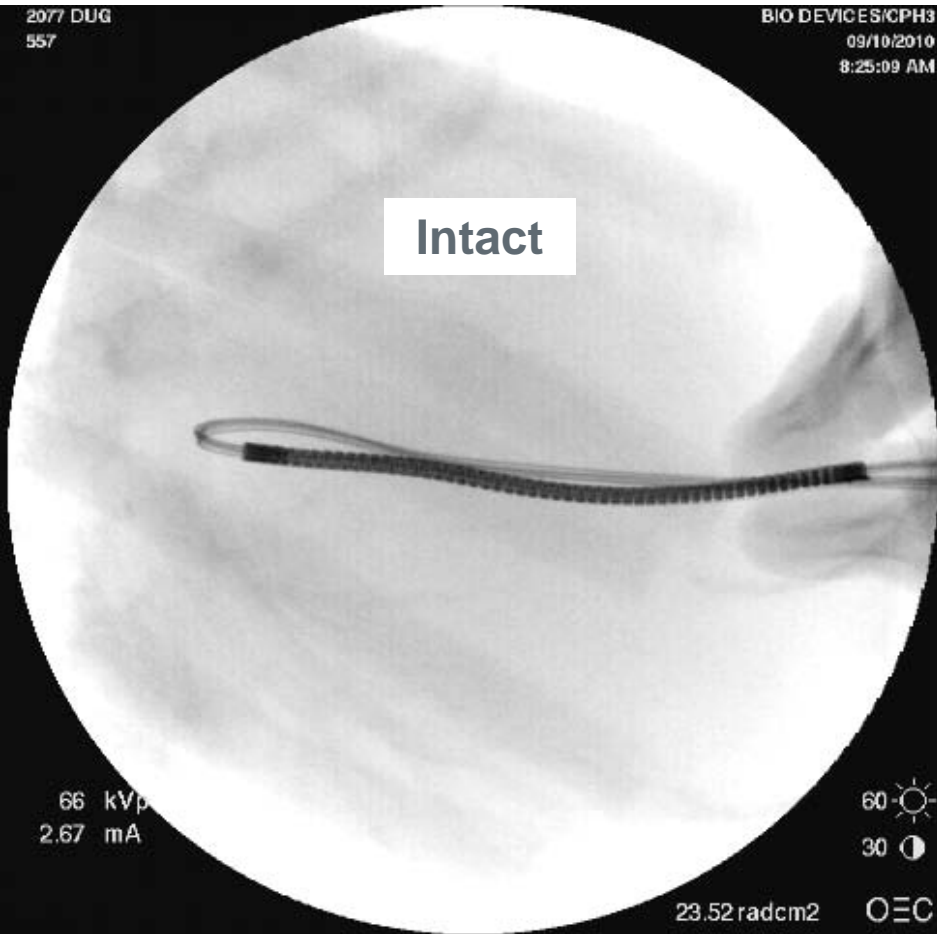# Normal Riata 1580 with Intact Insulation (No Externalized Cables)



# Normal Riata 1580 with Intact Insulation (No Externalized Cables)



# Normal Riata 1580 with Intact Insulation (No Externalized Cables)




# Examples of Intact Riata Leads

(Bends and Twists Have Been Induced)



# Examples of Intact Riata Leads

(Bends and Twists Have Been Induced)





# Determination of Externalized Conductors (ECs)



**ST. JUDE MEDICAL™**  
MORE CONTROL. LESS RISK.

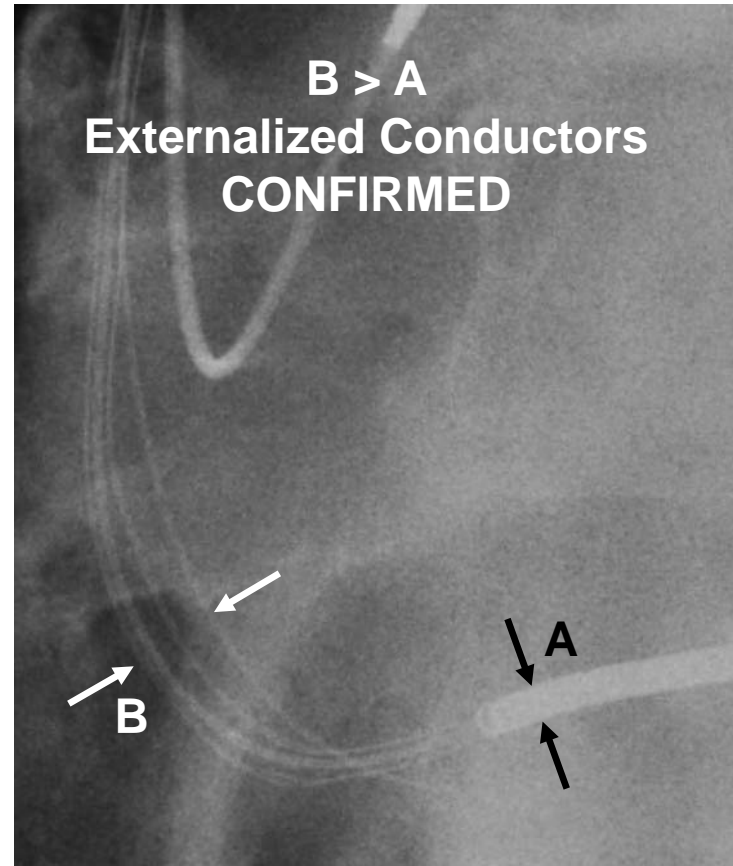
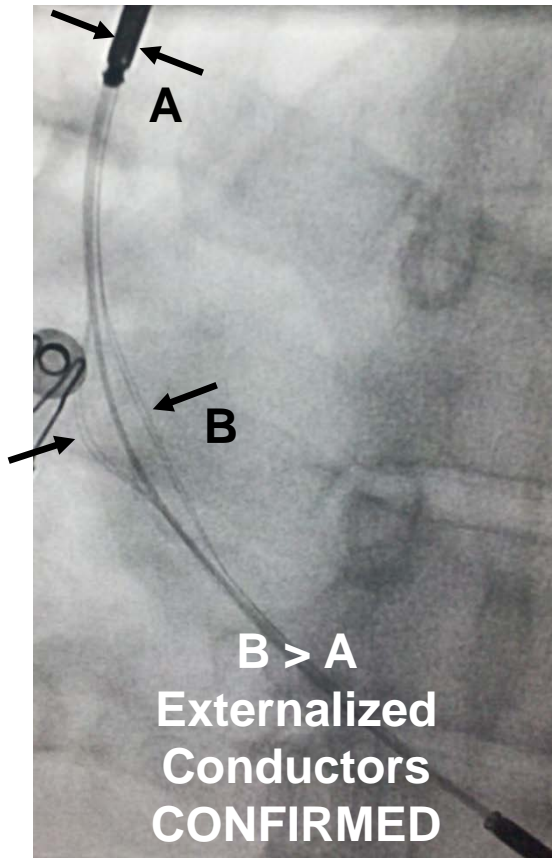
# EC Assessment – Step 1

The Riata lead should be examined along the entire length visible in the image. Attention should be focused on any areas where conductor(s) appear to be separated from the rest of the lead, even if only slightly.

***An externalized conductor exists if all of the lead conductors do not fit within the shock electrode shadow width.***

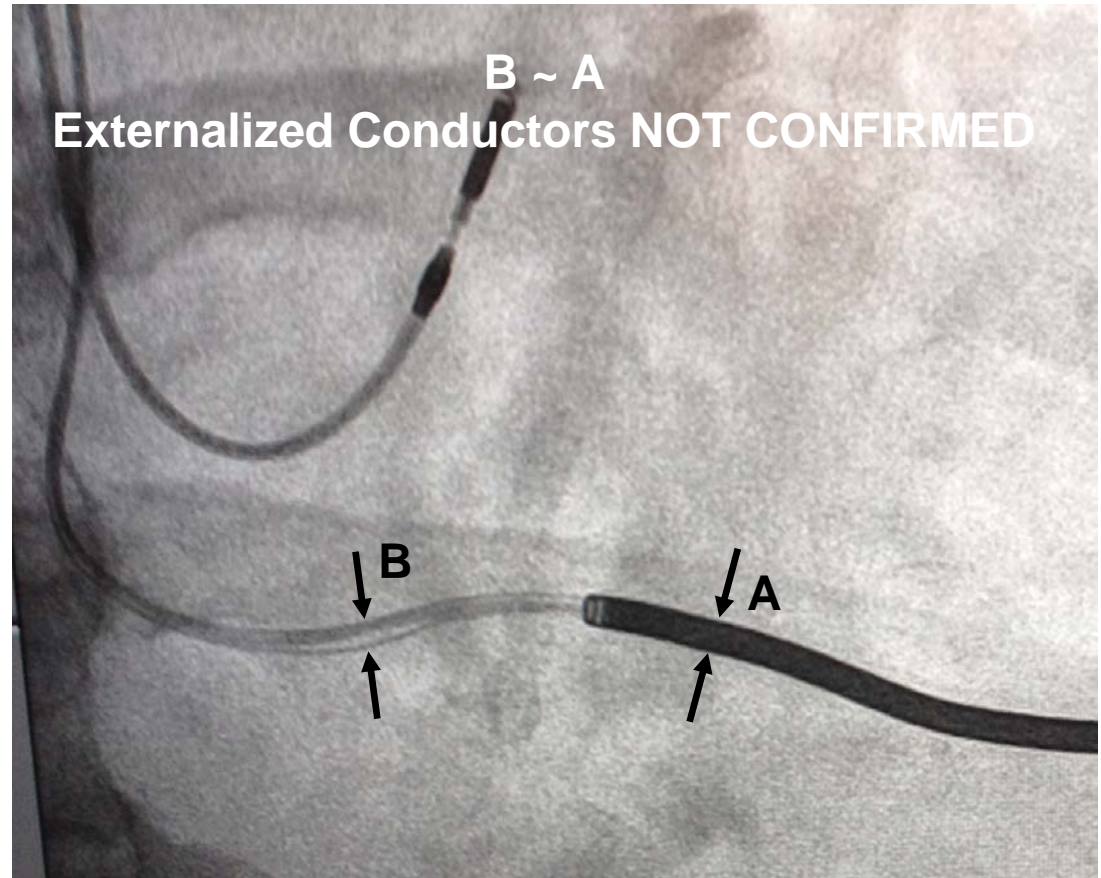
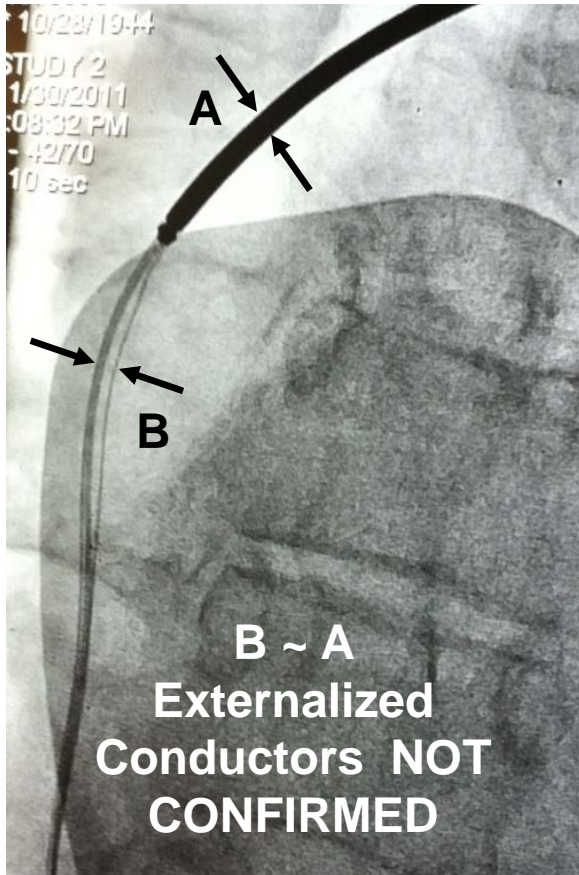
# EC Assessment – Step 1

At any point along the lead, is the distance across the conductors (B) larger than the diameter of a shock coil shadow (A)?



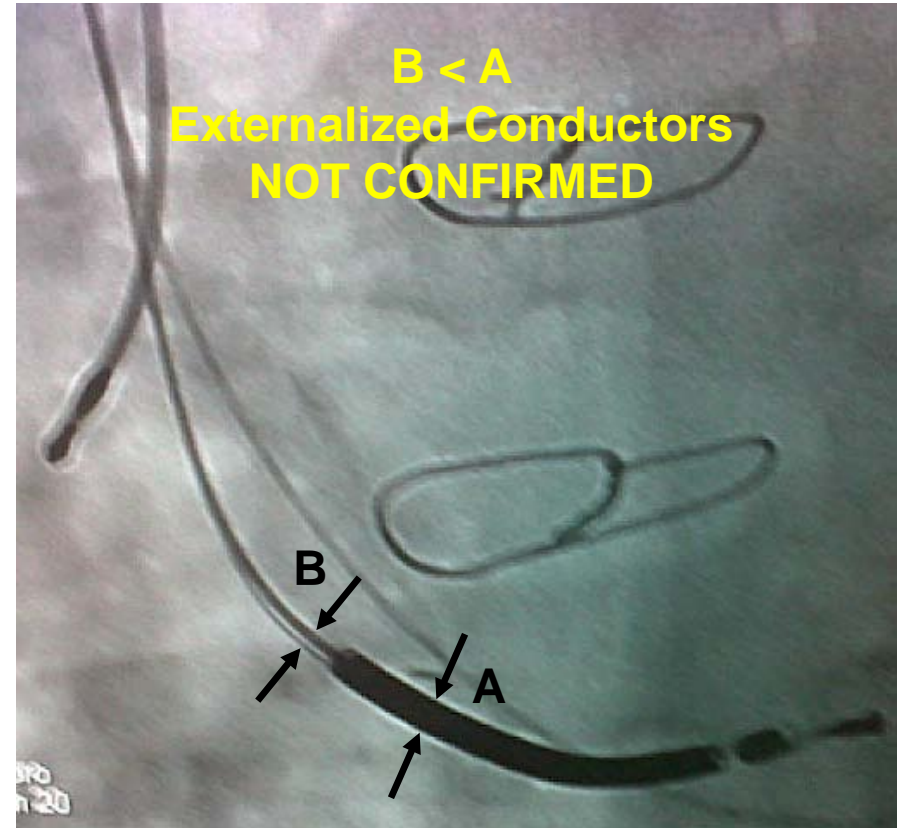
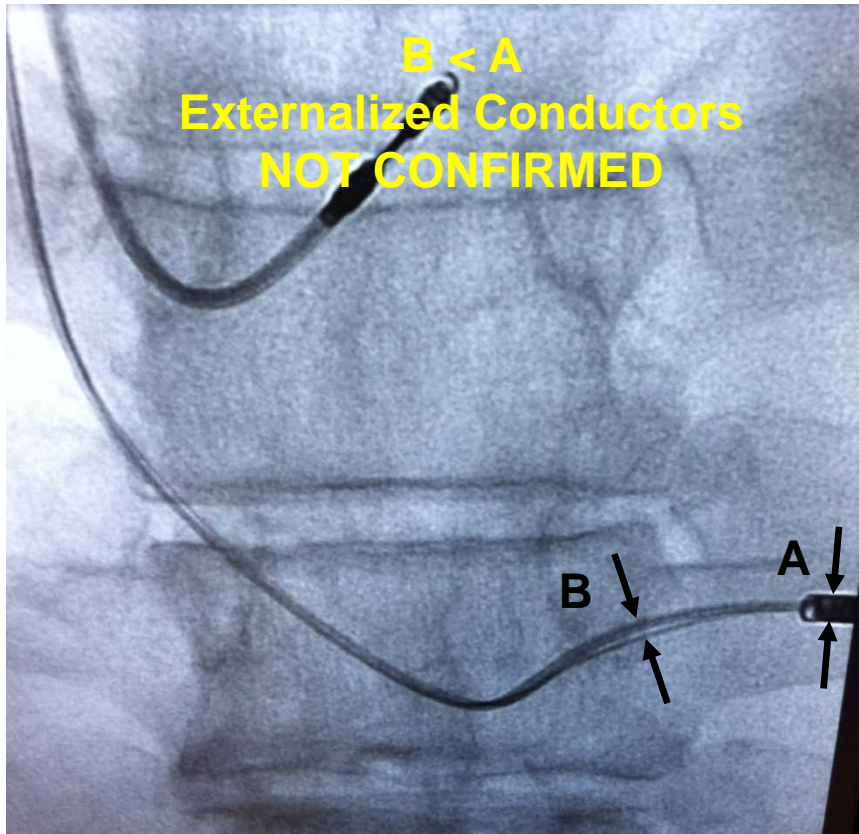
# EC Assessment – Step 1

At any point along the lead, is the distance across the conductors (B) larger than the diameter of a shock coil shadow (A)?



## EC Assessment – Step 1

At any point along the lead, is the distance across the conductors (B) larger than the diameter of a shock coil shadow (A)?

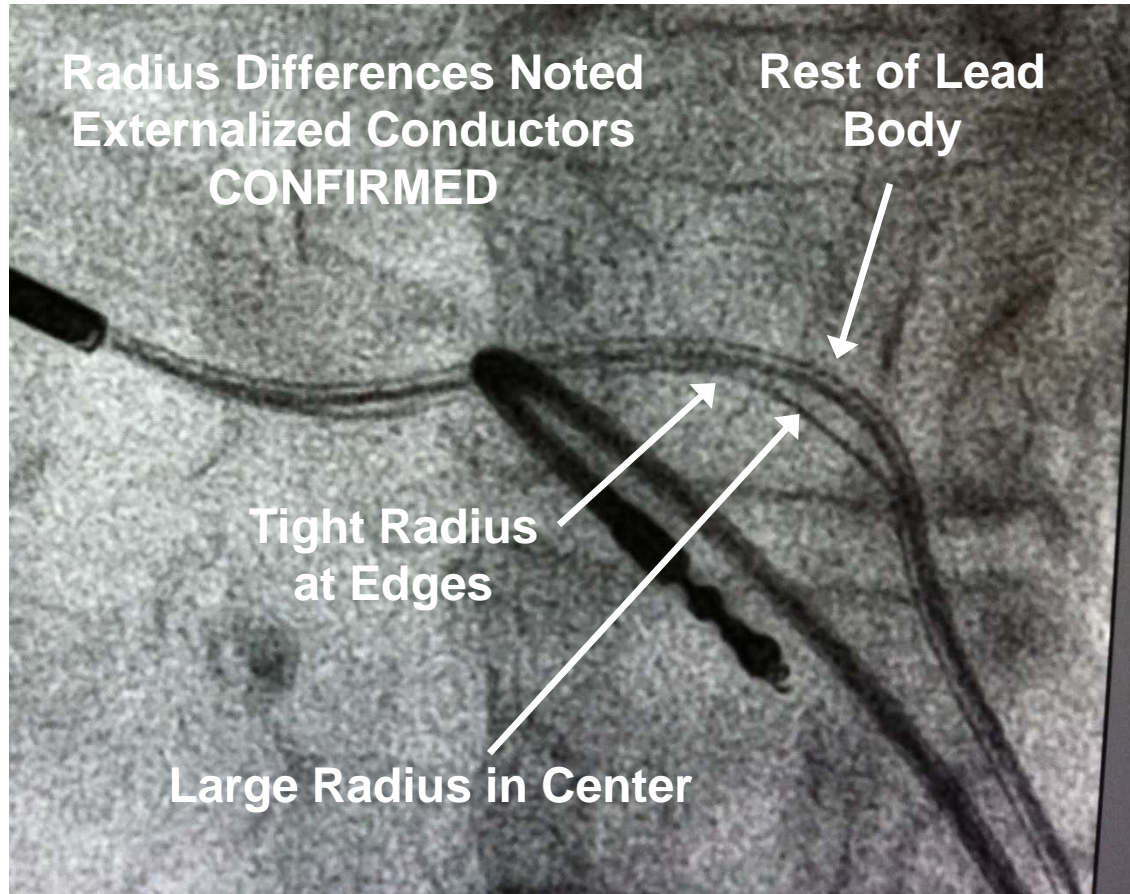


## EC Assessment – Step 2

The pathway of the externalized conductor must be carefully assessed for its radius of curvature. In most cases externalized conductors have a different radius of curvature than the rest of the lead body. If the suspected externalized conductor occurs on the inside of a bend, the center of the conductor length has a radius of curvature that is larger than the rest of the lead body. While occurring less commonly, it is also possible to have suspected externalized conductors on the convexity of a bend. In this case, the suspected externalized conductor will have a smaller radius of curvature than the rest of the lead body. It is important to note the radius of curvature at the edges of the suspected externalized conductor area. At the edges, externalized conductors tend to have an abrupt change in pathway, marked by a small, localized radius of curvature. An externalized conductor is identified when ***the radius of curvature of the suspected externalized conductor is significantly different than the rest of the lead body.***

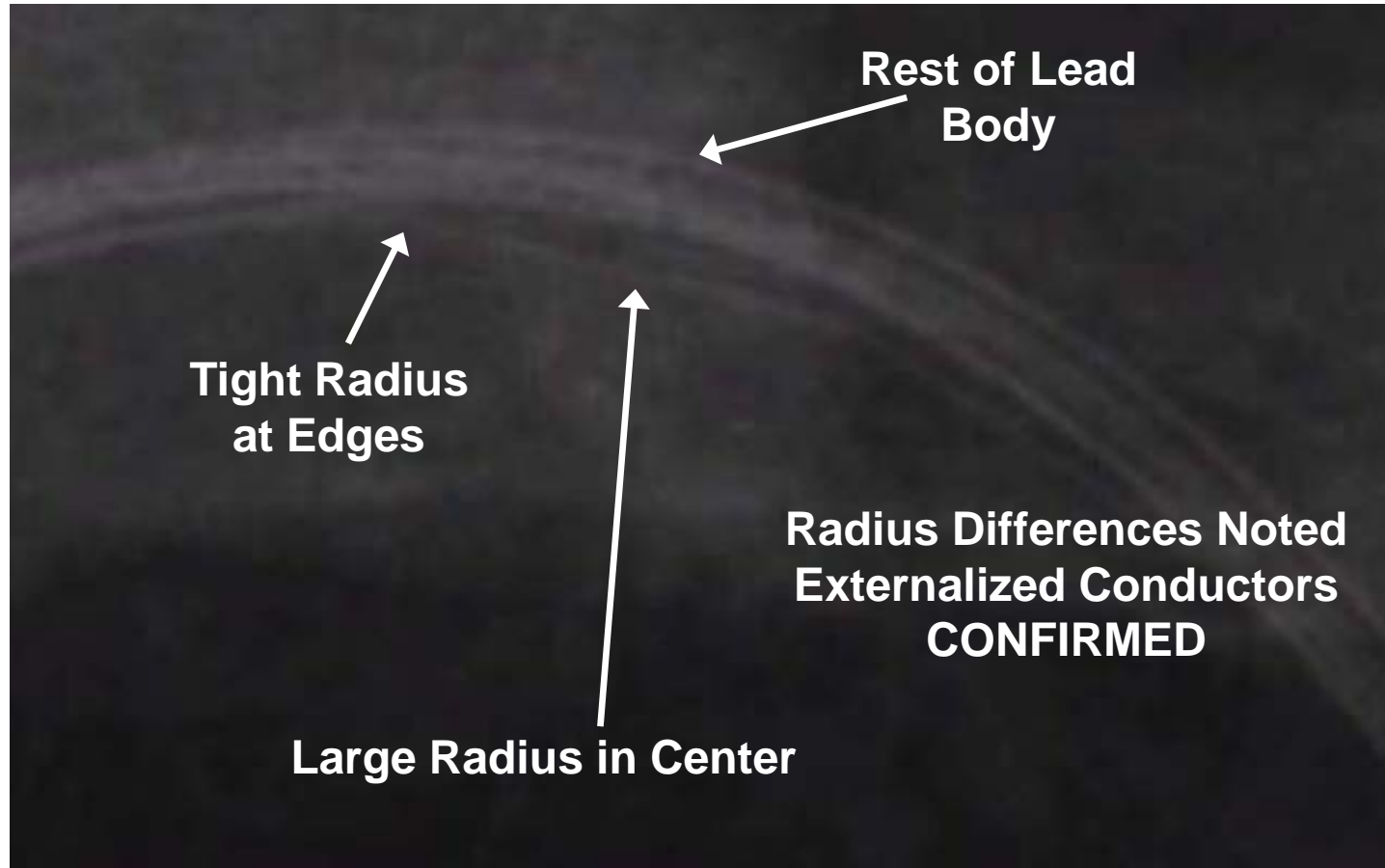
## EC Assessment – Step 2

Is the radius of curvature of any suspected externalized conductor significantly different than the rest of the lead body?



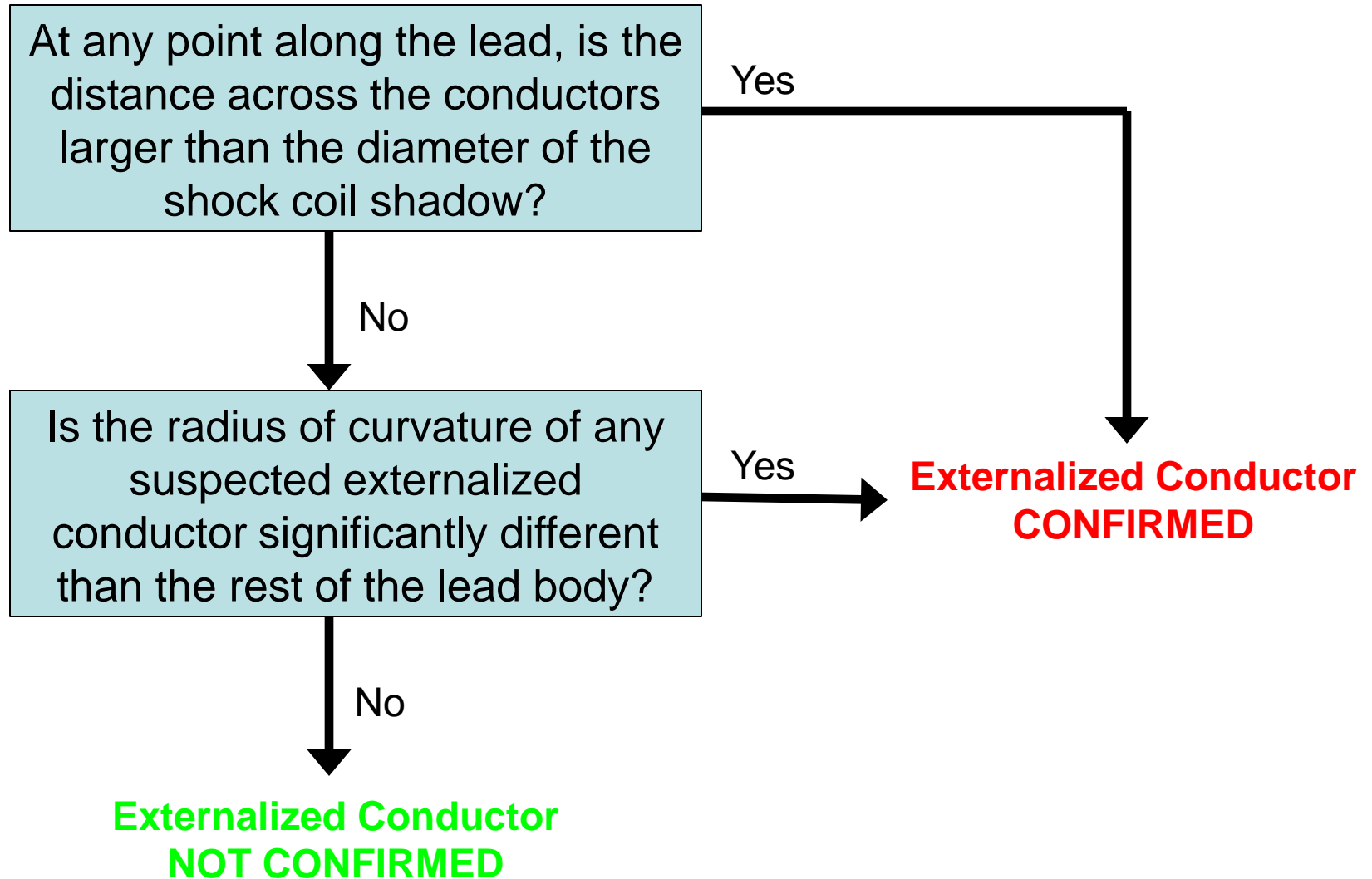
## EC Assessment – Step 2

Is the radius of curvature of any suspected externalized conductor significantly different than the rest of the lead body?



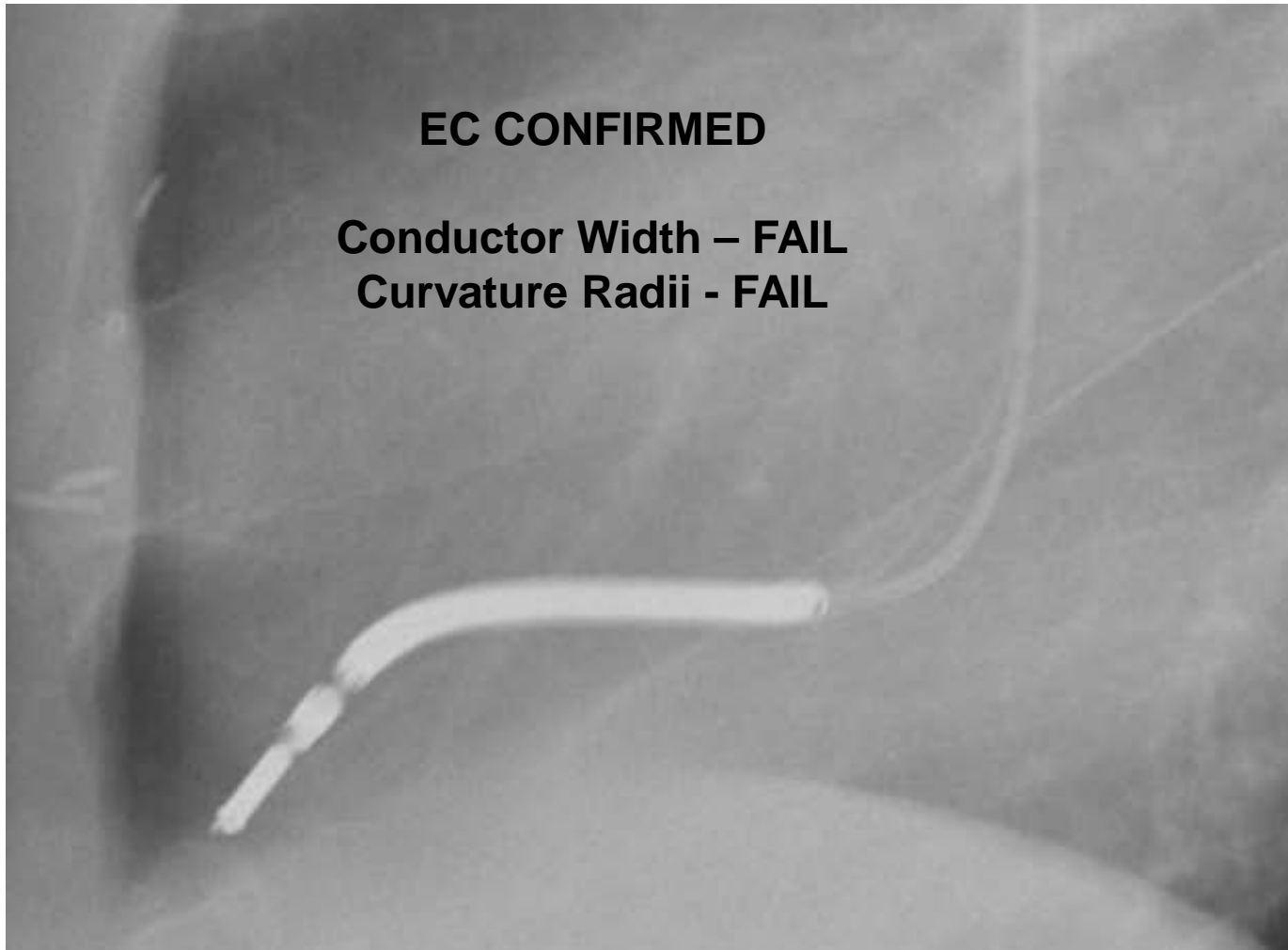


# Externalized Conductor (EC) Assessment Process



# Examples of EC Determinations

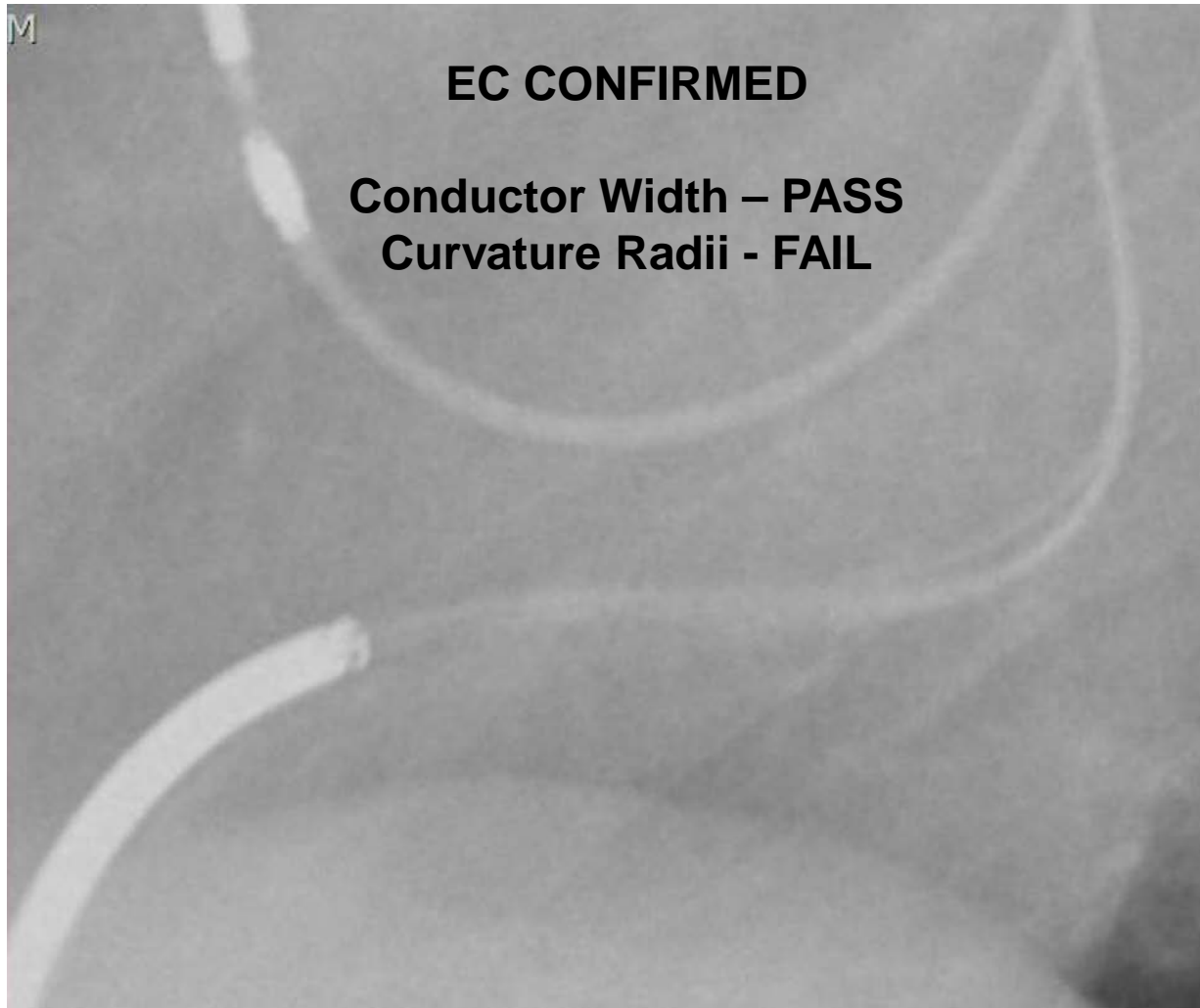
# Externalized Conductors?



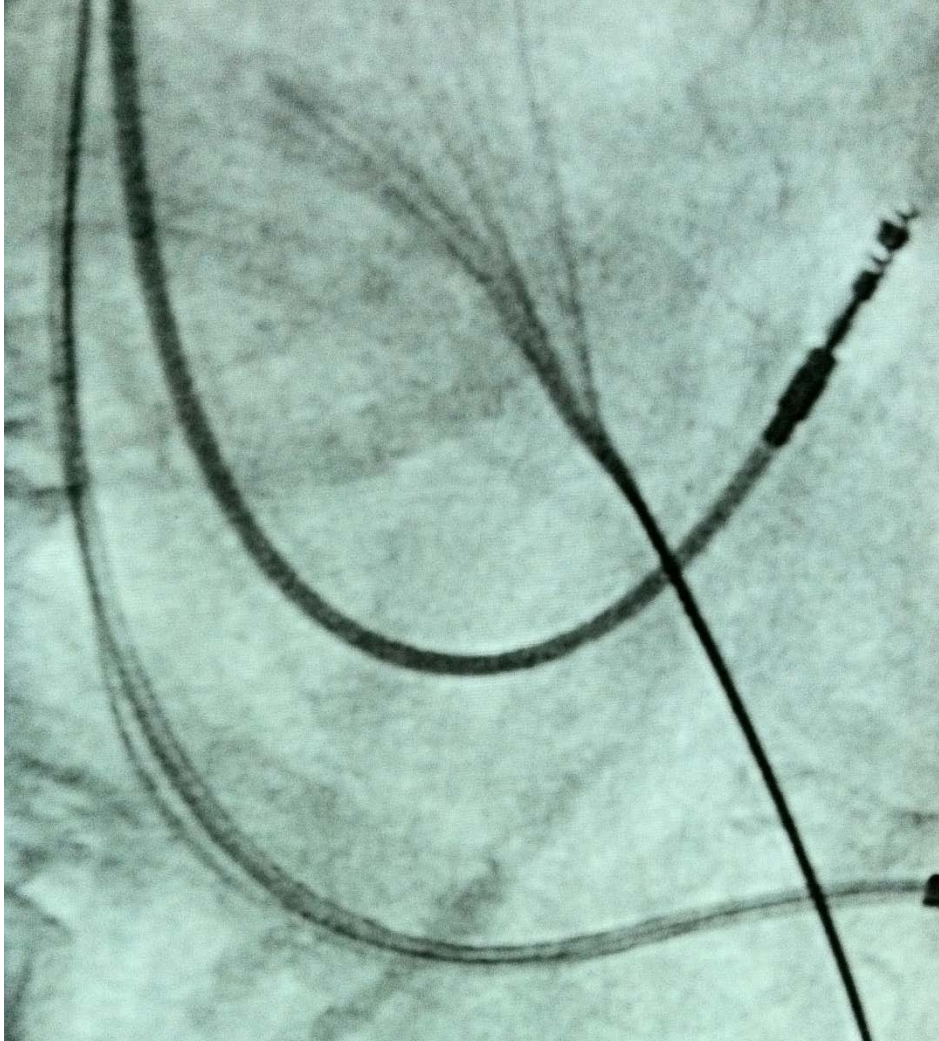
**EC CONFIRMED**

**Conductor Width - FAIL**  
**Curvature Radii - FAIL**

# Externalized Conductors?



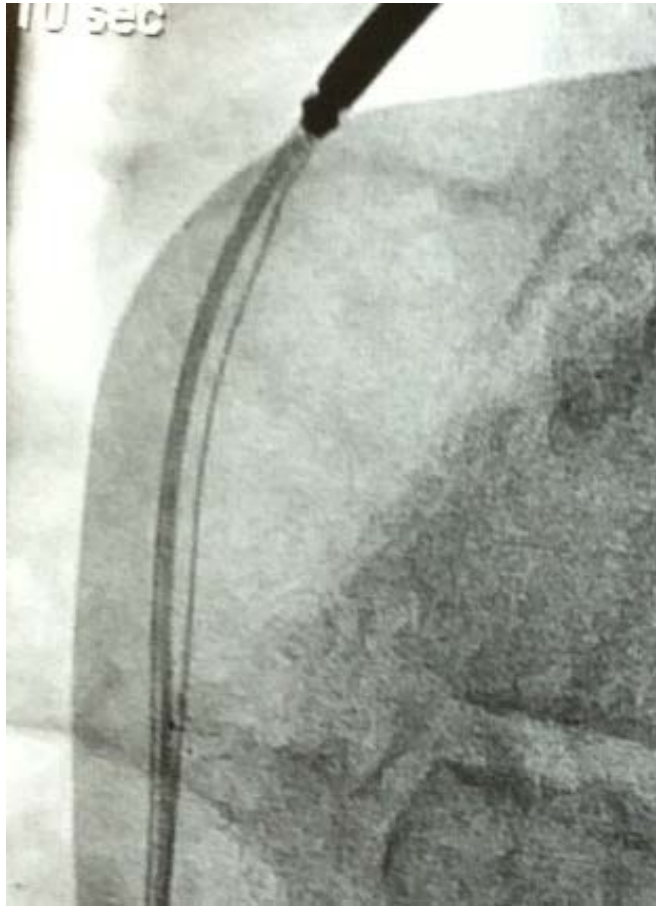
# Externalized Conductors?



**EC CONFIRMED**

**Conductor Width – FAIL**  
**Curvature Radii - FAIL**

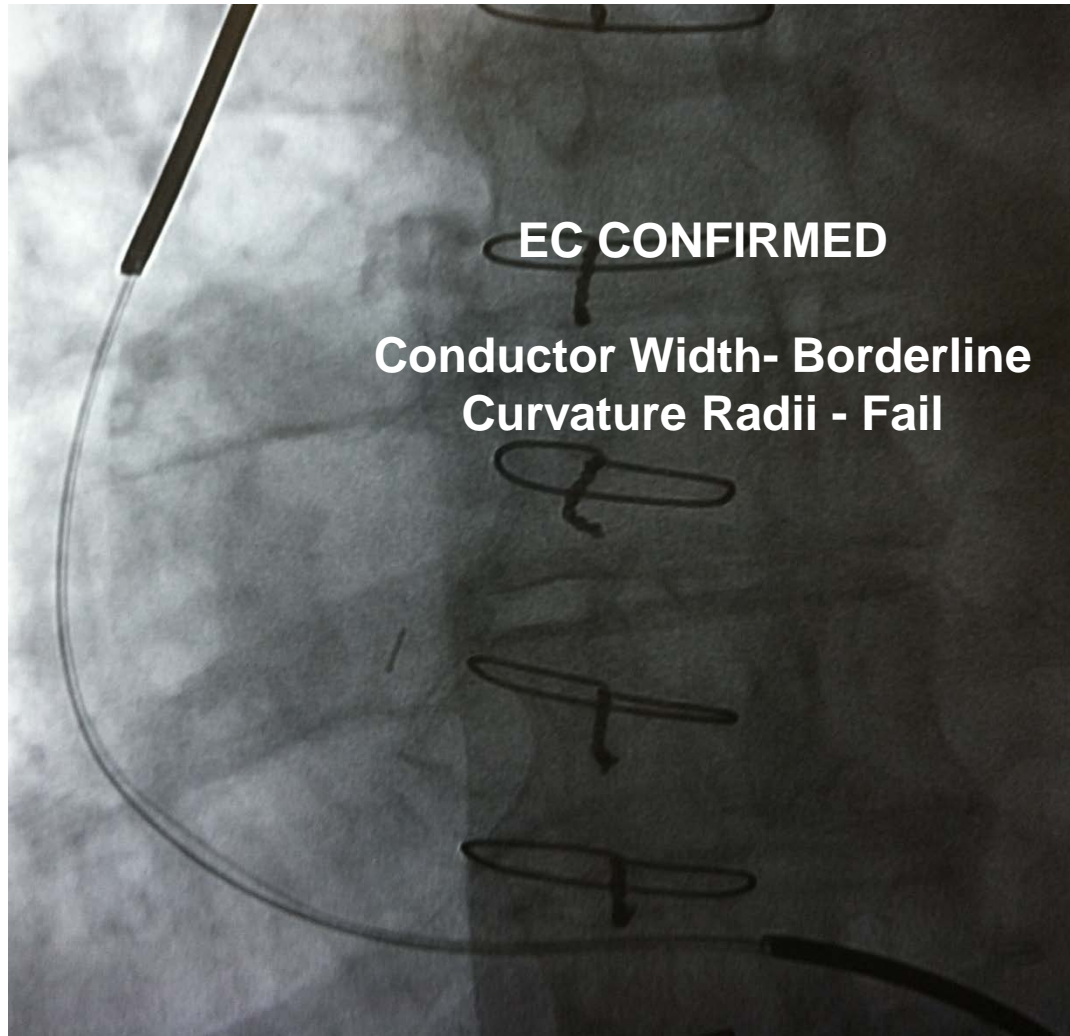
# Externalized Conductors?



**EC CONFIRMED**

**Conductor Width – Borderline  
Curvature Radii - FAIL**

# Externalized Conductors?

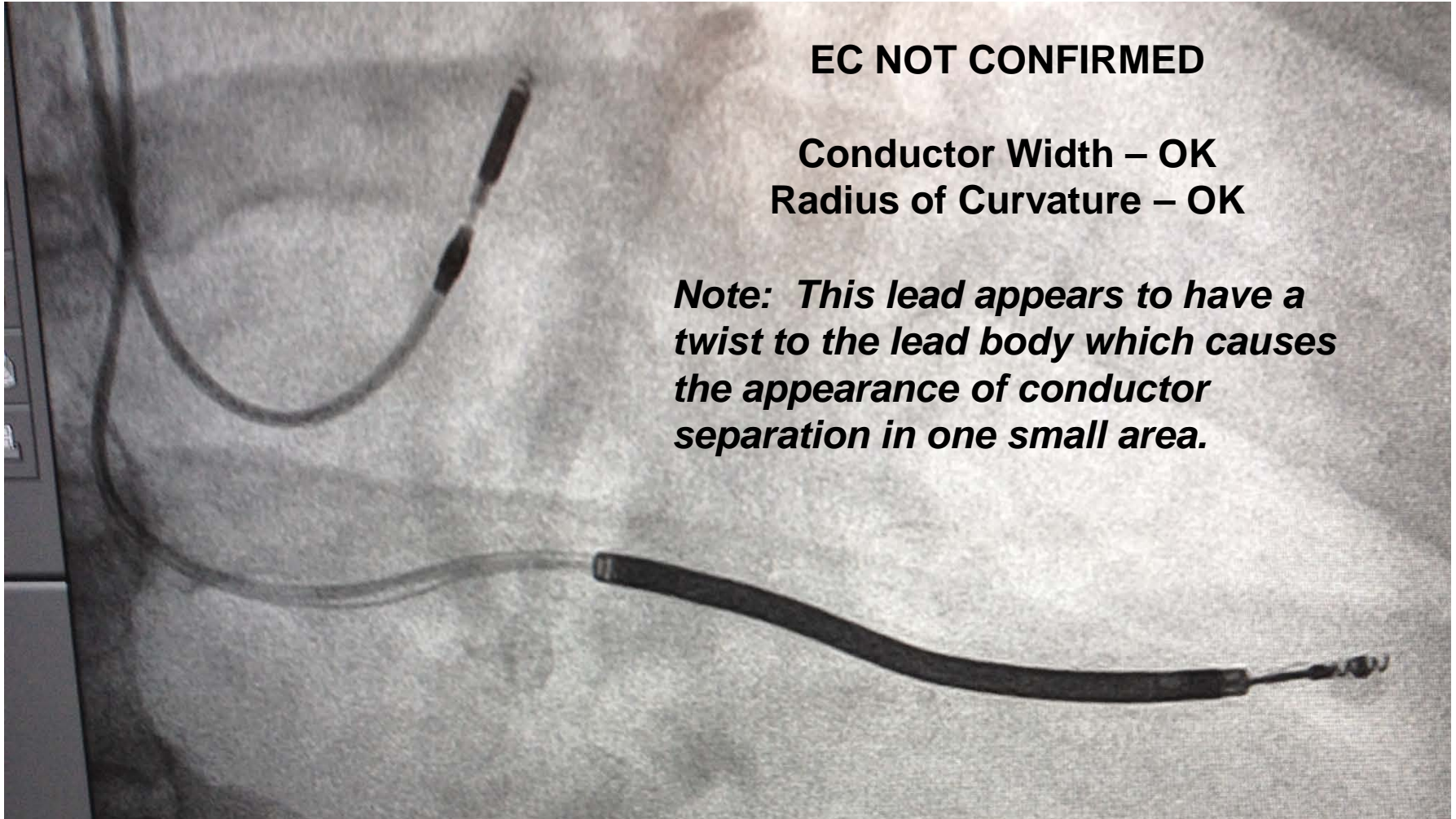


# Externalized Conductors?

**EC NOT CONFIRMED**

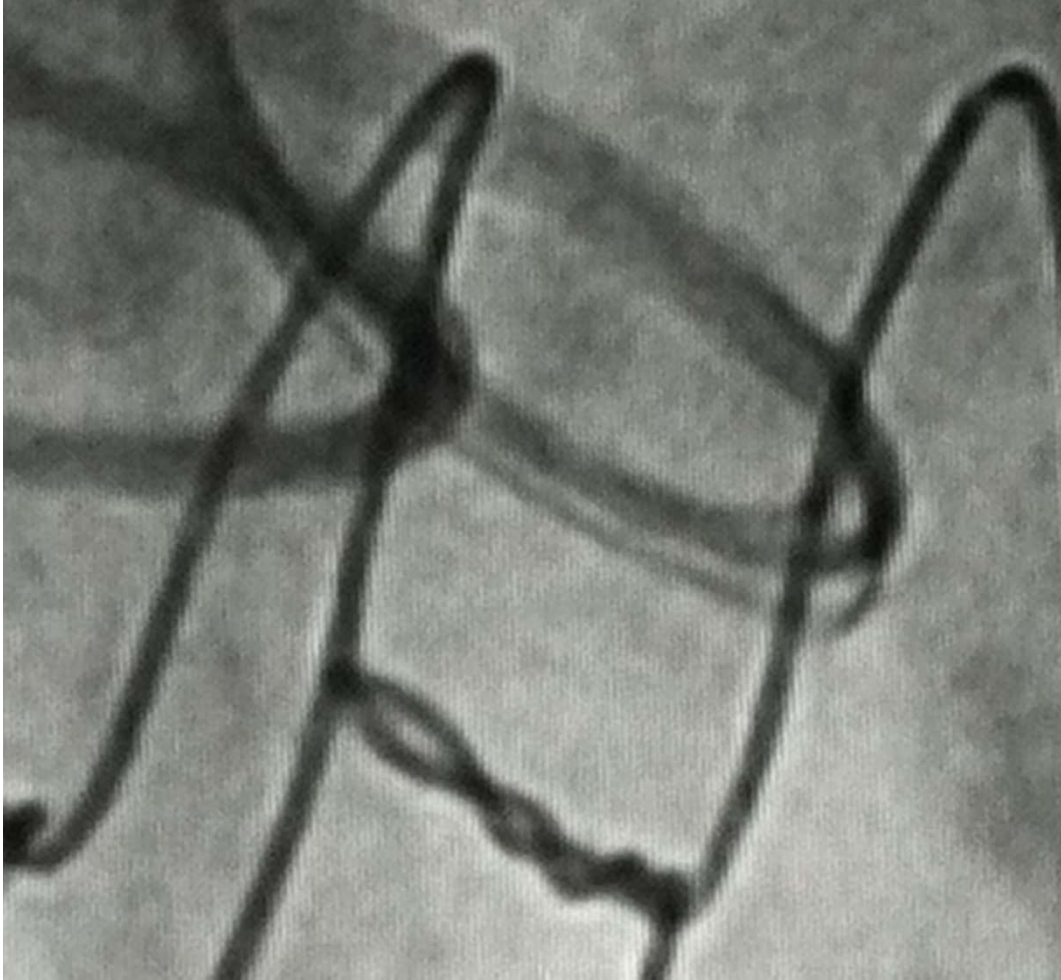
**Conductor Width – OK  
Radius of Curvature – OK**

***Note: This lead appears to have a twist to the lead body which causes the appearance of conductor separation in one small area.***





# Externalized Conductors?

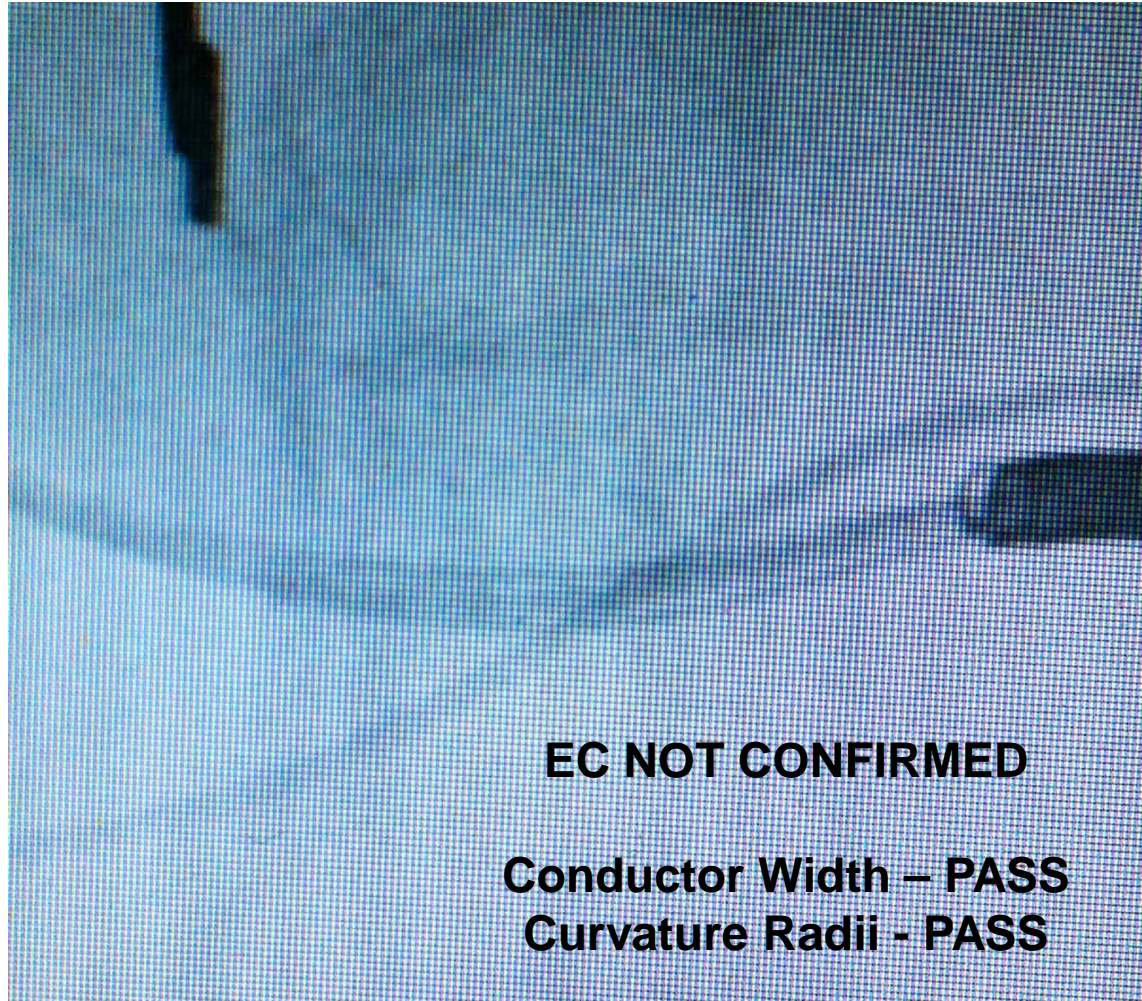


**EC CONFIRMED**

**Conductor Width – N/A  
(no shock coil visible)**

**Curvature Radii - FAIL**

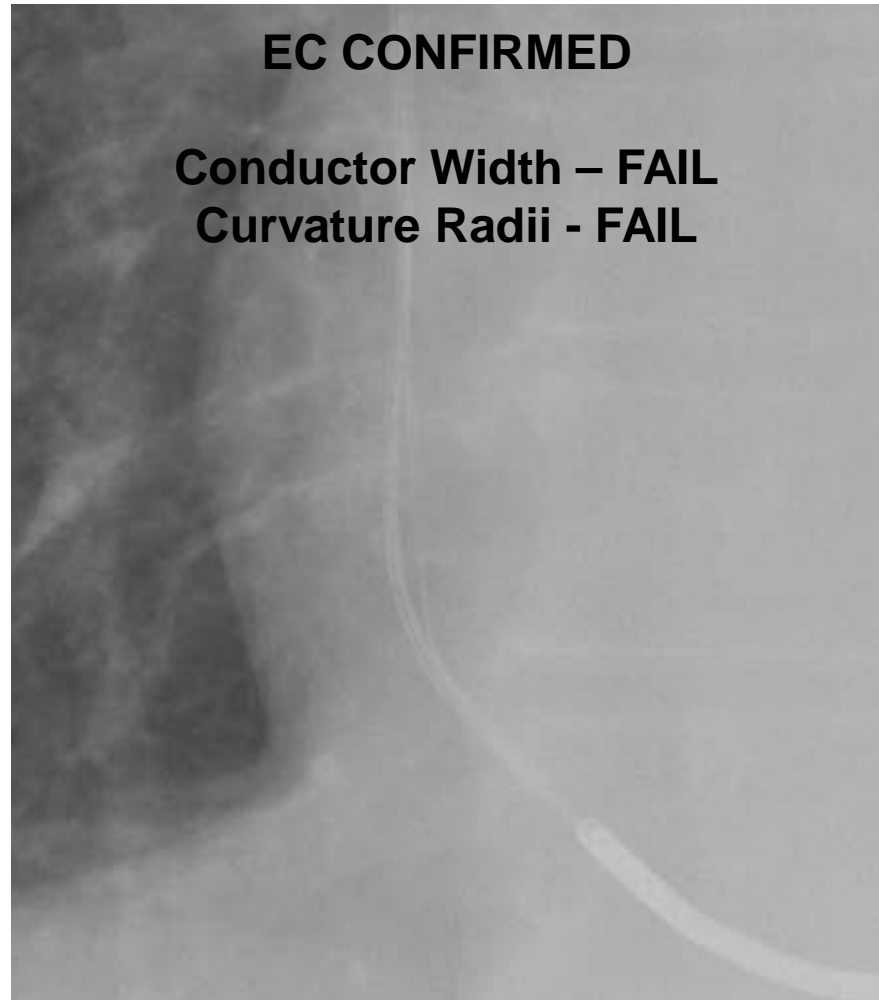
# Externalized Conductors?



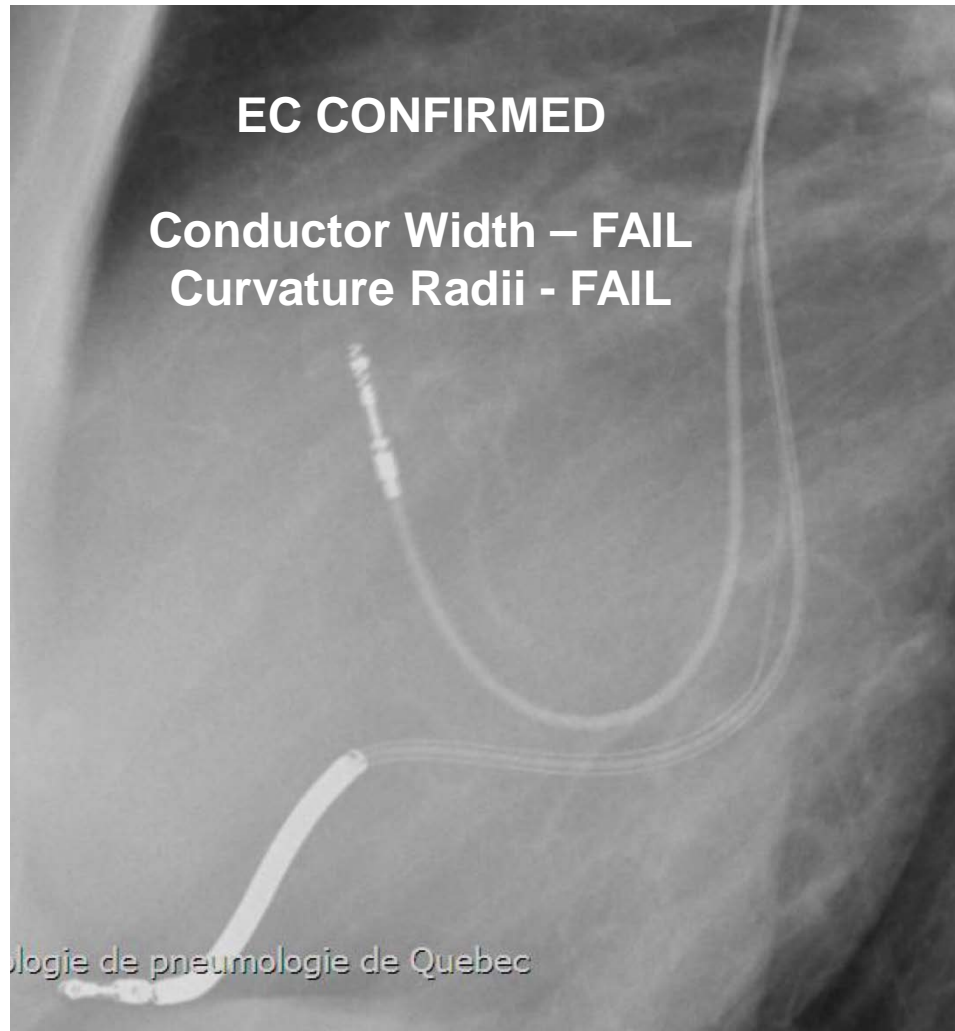
**EC NOT CONFIRMED**

**Conductor Width – PASS**  
**Curvature Radii - PASS**

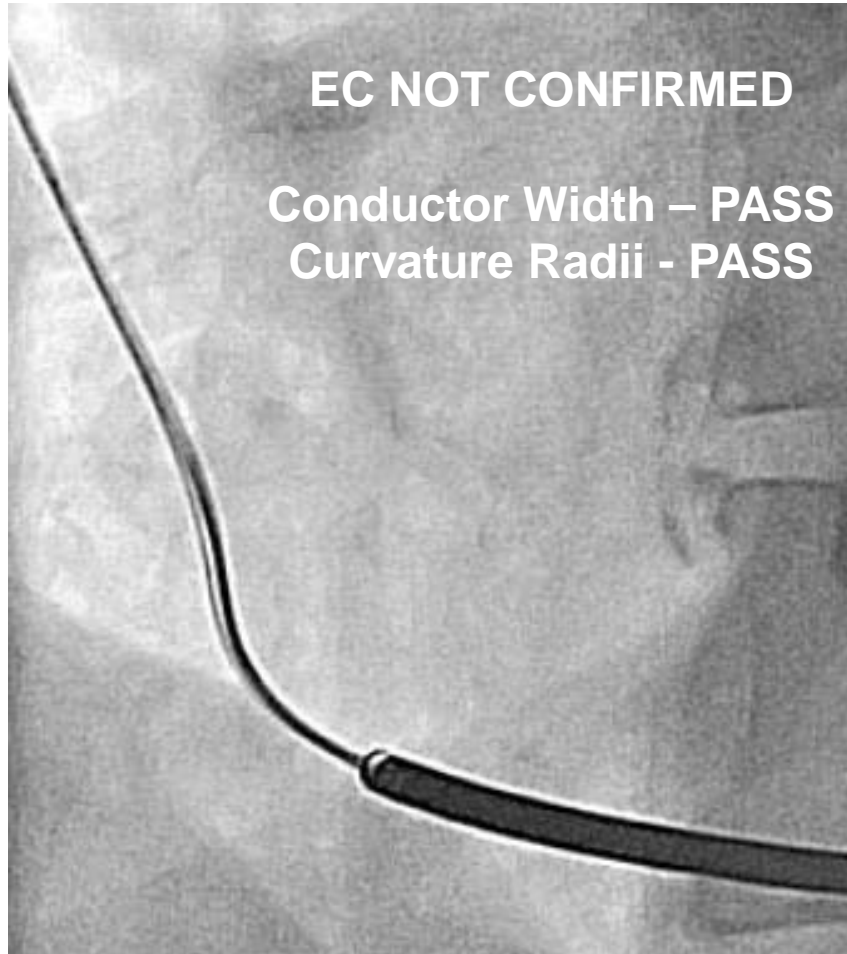
# Externalized Conductors?



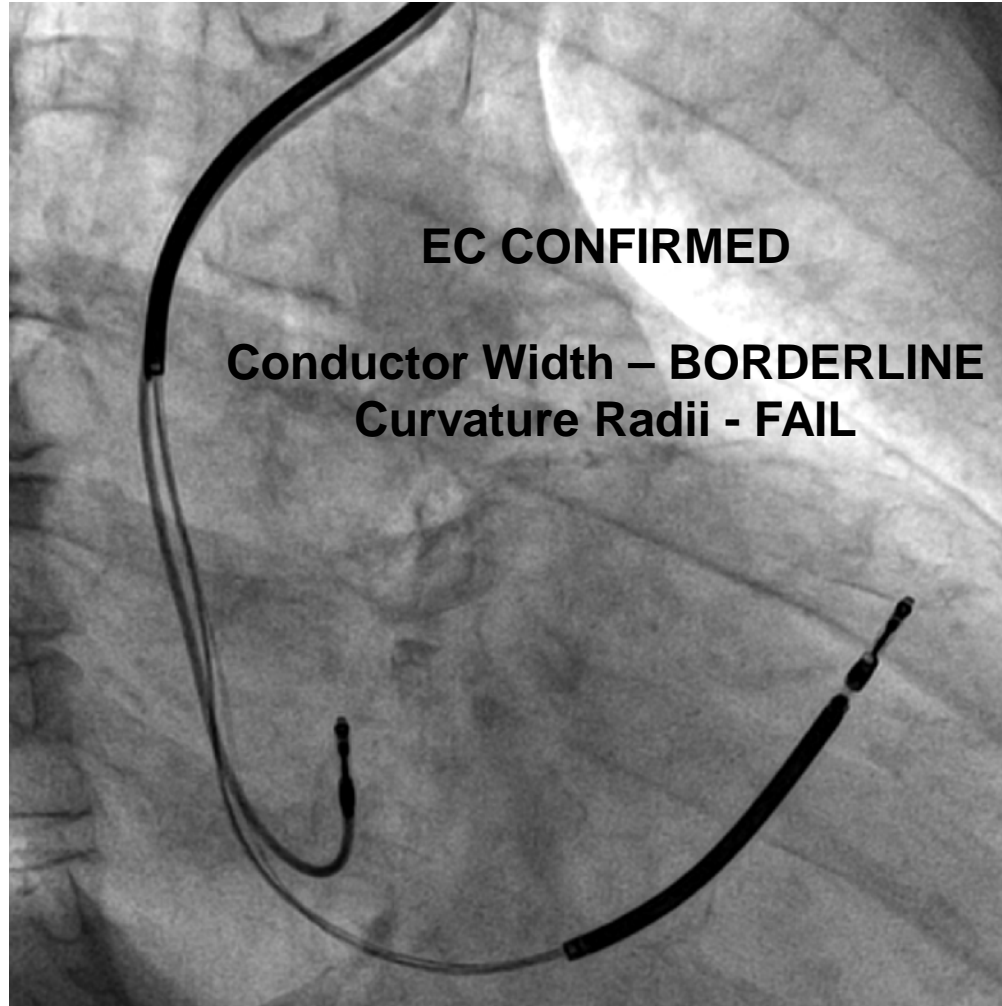
# Externalized Conductors?



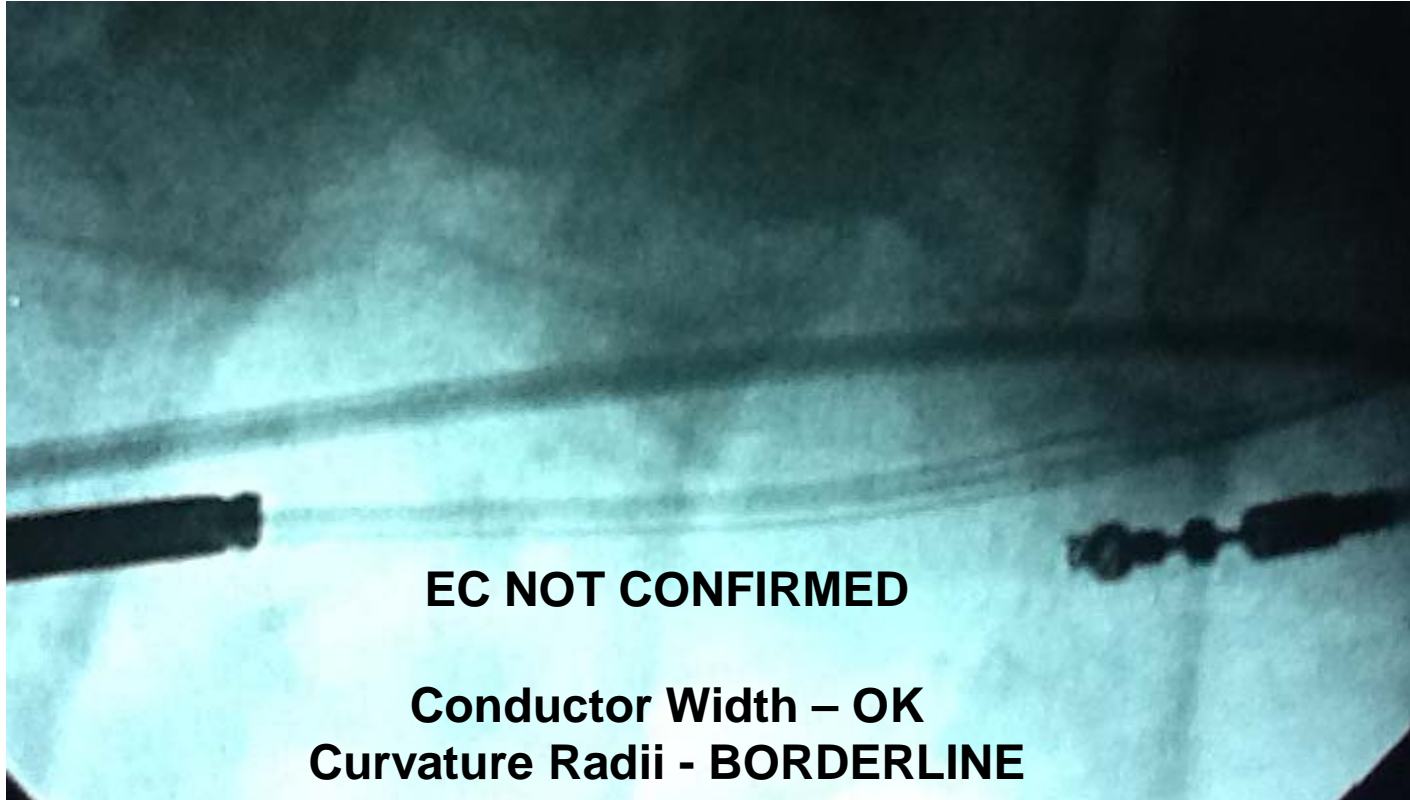# Externalized Conductors?



# Externalized Conductors?



# Externalized Conductors?



**EC NOT CONFIRMED**

**Conductor Width – OK**  
**Curvature Radii - BORDERLINE**

**EC should not be confused with wires that are Normally present in the device pocket. Arrows represent wires within the DF-1 pin proximal to the yoke of the lead**

